

Anterior open bites: old problem, new solutions

Paul Humber explains how to solve this common problem with various treatment methods

Background

An anterior open bite can be defined as a situation where the lower incisors are not overlapped in the vertical plane by the upper incisors and do not occlude with them (MacDonald 1998). Its prevalence in adults is about 4% and can vary between ethnic groups so that, for example, the incidence amongst Afro-Caribbeans has been measured as high as 10% (Burford 2003). Care should be taken with early diagnosis, as the incidence tends to fall between the age of nine or earlier and teens as the occlusion develops, as digit sucking tends to decrease and as adult swallowing patterns become more established. The incidence of anterior open bite then tends to increase again during the teens to early adulthood as vertical facial growth continues and concludes.

Indications for treatment

Patients are most likely to be preoccupied with the aesthetic aspects of anterior open bites but issues such as speech impediments and difficulty incising food may also be explored. There is only scant evidence that closing an anterior open bite can help speech and certainly this should not be offered as a reason for treatment because the outcome is uncertain (Ferguson 1995). If other aspects of the occlusion are within normal parameters, then an AOB of 4mm in itself places the dentition into the IOTN 4.



Paul Humber is a partner at Hopvine House Dental Surgery, Soham. He is a Clinical Speaker for Align Technology and has treated over 850 patients using the Invisalign Technique. www.sohamdental.co.uk



Education aims and objectives

The aim of this article is to educate the reader about the various treatments for anterior open bites.

Expected outcomes

The reader will understand the indications for treatment, how to plan and the new methods that can be used to create an aesthetically pleasing result.

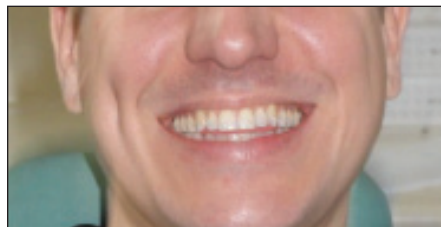

Figure 1: Patient A pre-treatment

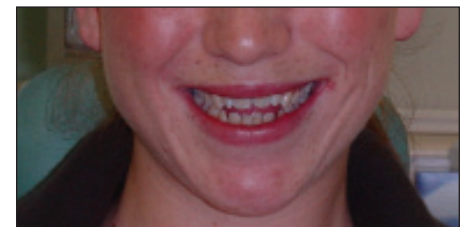


Figure 2: Patient B pre-treatment

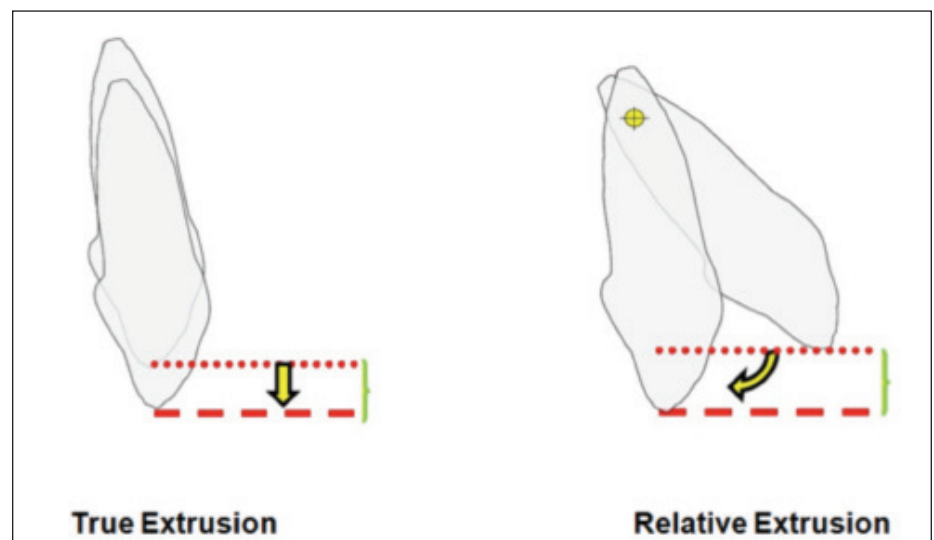


Figure 3: Courtesy of Align Technology

Treatment planning

With anterior open bites, as with much of orthodontics, no one remedy suits all cases. It should not be assumed that an AOB in its own right leads to poor facial appearance, and if it is to be treated, the same AOB may require different remedies for different patients. For

example, Figure 1 and Figure 2 show two patients where the AOB between the UL1 and LL1 are the same, but aesthetically, the patients look markedly different and had different concerns. Different levels of proclination, different lip lines and the differing contribution of the mandibular and maxillary size and angulation all require different strate-

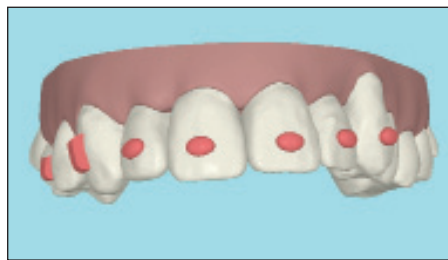

Figure 4: A 'ClinCheck' from an early Invisalign case showing the traditional composite attachments in red

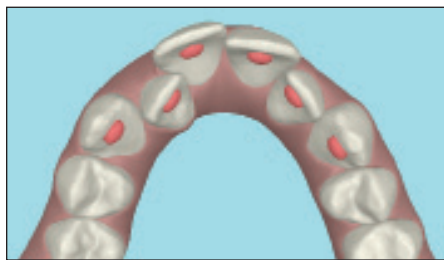

Figure 5: A 'ClinCheck' of Patient C

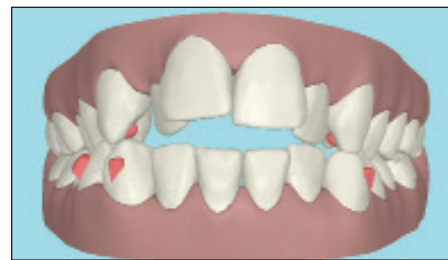


Figure 6: A 'ClinCheck' of Patient C

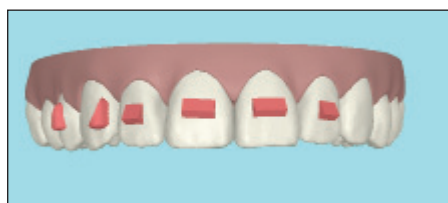

Figure 7: A 'ClinCheck' showing the shape of Invisalign's new 'optimised attachments' in red.

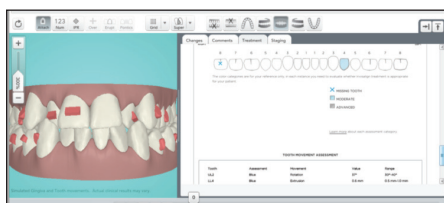


Figure 8: A ClinCheck plan showing a tooth movement assessment

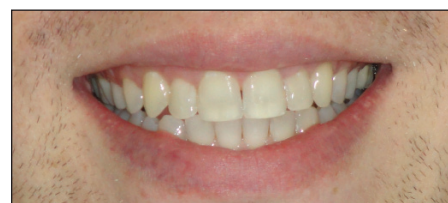

Figure 9: Patient C after a year of treatment with Invisalign




Figure 10: Patient B after 15 months of treatment with Invisalign

gies. Among other things therefore, it pays at the outset to take a range of photographs intra-orally and extra-orally from different angles. Adult patients will have views about what they are trying to achieve, so it is good practice to look at these photographs together with the patient and record the conclusions you both draw.

The degree of skeletal involvement should be ascertained, because surgery may need to be part of any remedial treatment, and with the teeth themselves, a particular aspect to clarify is the extent to which proclination of the incisors are contributing to AOB: as an incisor tilts palatally to become vertical it will afford some relative extrusion as a result (Figure 3).

Methods of treatment

Fixed appliances, removable appliances, myofunctional therapy such as posterior bite blocks, and surgery have all been employed over the years to address AOBs. In the deciduous dentition, a simple cessation of thumb or dummy sucking is usually the only solution that need be considered: the improvement can then take up to five years and may not occur until the permanent dentition erupts, and so patience and monitoring can be key strategies (Bowden 1966). In older age groups

where the patient is still growing, posterior bite blocks are more common; the procedure is typically to open the bite by 3-4mm beyond the resting position in an attempt to inhibit vertical growth of the buccal dento-alveolar bone while allowing the eruption of anterior teeth (Burford 2003).

More recently, clinicians have been treating anterior open bites with Invisalign®. Invisalign is an orthodontic system where we can design treatment plans using Align Technology's ClinCheck® software, while simultaneously drawing on Invisalign's experience of treating over a million patients. A series of clear 'aligners' are then created for the patient to wear, which simultaneously straighten the teeth.

The advantages of the Invisalign System as a whole are well known: the aligners are virtually invisible, and are removable and comfortable (Miller 2007); this minimises the inconvenience to the patient and allows good oral hygiene (Taylor 2003). Because the treatment is planned utilising a specialised software, it is possible to plan the degree to which the clinician is hoping to extrude the upper incisors and the degree to which the lower incisors will be moved.

Kucukkeles (1999) studied the closure of AOBs using fixed appliances and anterior elastics, and discovered that the bulk of the

closure was achieved by a combination of the uprighting of the upper incisors and the extrusion of the lower incisors. This was true even when it would have been desirable to extrude the upper incisors and not extrude the lower incisors at all. With Invisalign, if we did not want to extrude the lower incisors, then we could simply programme into the ClinCheck plan to not extrude the lower incisors.

The number of methods open to the clinician to extrude teeth with Invisalign have multiplied as the system has been developed. Results of research have been fed back into the process, resulting most recently in the creation of SmartForce features. It is usually desirable for the teeth to have composite attachments placed on any teeth that require more than 0.4mm of extrusion and in the early years of the technique, these were often simple round or ellipsoid shapes. These were usually placed labially, as in this case started in January 2010 (Figure 4) or sometimes palatally (Figures 5) so that they are less visible anteriorly (Figure 6). But research and development involving mathematical modelling, and both in vitro and in vivo studies has led to the progressive SmartForce features such as 'Optimized Attachments' which take into account the exact size and shape of a tooth, and the precise movements required of it. An attachment is

then designed by specialised software and placed at the optimal position on the relevant tooth. An example of this is shown in Figure 7 where no two attachments are identical in size, shape or position.

With the advent of Invisalign's G3, these innovations have been applied to more teeth in each arch, and have been combined with a host of new features including a computerised tooth movement assessment. This can be brought up on screen such as in Figure 8 where we can learn the exact nature of any difficult movements we are requiring of the teeth. A tooth with moderately difficult movements to make is shown in blue, and the degrees of rotation or torque, or the millimetres it has to move are measured by the computer. A tooth that requires advanced movements is shown in black, and their movements are also calibrated in the same way.

The traditional Invisalign system has proved perfectly adept at treating anterior open bites. The patient shown in Figures 5 and 6 can be seen one year later nearing completion as a case (Figure 9) while the patient shown in Figure 2 took 15 months to get to the stage shown in Figure 10. In both instances, the treatments needed monthly supervision to check that the aligners were fitting well at each visit and sometimes the composite attachments needed replacing to allow a better fit within the aligner. An aligner that fitted poorly on an ellipsoid attachment could result in the tooth intruding instead of extruding. In both cases, the patients needed secondary sets of aligners, known as 'refinement aligners' to complete the case. It is hoped that with the new innovations we will see a higher incidence of cases that complete faster and with ever increasing predictability.

Retention

Anterior open bites are known to have a high relapse rate with one longitudinal 10-year study (Lopez-Gavito 1985) showing that 35% of cases showed a post retention open bite of 3mm or more when examined a minimum of 9.5 years later. Fixed retention may be a popular and sensible option therefore.

Conclusions

Anterior open bites are found in about 4% of the adult population and have been treated using a variety of techniques. Fixed appliance techniques have been found to rely largely on lower incisor extrusion and

upper incisor uprighting and have been shown to have a high relapse rate. Newer techniques such as Invisalign allow for a greater degree of planning at the outset and with new technological innovations should be shown to have ever increasing predictability like the SmartForce features. Retention will probably always be an issue with anterior open bite treatment and so fixed retention should be considered. **A**

References

- Bowden, B.D., (1966) The effects of digital and dummy sucking on arch widths, overbite and overjet: a longitudinal study. *Australian Dental Journal* 11: 396-404
- Burford, D., and Noar, J.H., (2003) The Causes, Diagnosis and Treatment of Anterior Open Bite. *Dental Update* 30: 235-241
- Ferguson, J.W., (1995) The assessment and treatment of anterior open bite. *Dental Update* 22: 163-168
- Kucukkeles, N., Acar, A., Demirkaya, A. A., Evrenol, B., Enacar, A., (1999) Cephalometric evaluation of open bite treatment with NiTi arch wires and anterior elastics. *American Journal of Orthodontics and Dentofacial orthopaedics* 116: 555-562
- Lopez-Gavito, G., Wallen, T.R., Little, R.M., Joondeph, M.S., (1985) Anterior open-bite malocclusion: a longitudinal 10-year postretention evaluation of orthodontically treated patients. *American Journal of Orthodontics* 87: 175-186
- McDonald, F., and Ireland, A.J., (1998) *Diagnosis of the Orthodontic Patient*. Oxford University Press ISBN 0192628892
- Miller, K.B., McGorray, S.P., Womack, R., Quintero, J.C., (2007) A comparison of treatment impacts between Invisalign aligner and fixed appliance therapy during the first week of treatment. *American Journal of Orthodontics and Dentofacial Orthopedics* 131:302e 1-9
- Taylor, M.G., McGorray, S.P., Durrett, S., Pavlov, S., Downey, N., Lenk, M., Oxford, E., Dolce, C., Wheeler, T.T., (2003) Effect of Invisalign aligners on periodontal tissues. *Journal of Dental Research* 82 (Spec. Iss. A) 1483